Knee Bone Segmentation from MR Images using a Novel Deep Learning Method

Cristina-Petruta Manoila[1], Susana Kallioinen[2], Abhir Bhalerao[1], Andy Metcalfe[2], and Charles Hutchinson[3]
[1]Department of Computer Science, [2]Warwick Medical School, [3]Department of Radiology at UHCW

INTRODUCTION:

- The most prevalent articular disorder is OA (1) and affects people of every age causing stiffness, swelling, damage, and pain in the knees, hips, and small joints of the hands (2).
- A common technique that helps radiologists to make decisions swiftly in identifying OA is the computer-aided diagnosis (CAD) based on magnetic resonance imaging (MRI).
- The aim of this work is to predict an accurate segmentation of bones from MR images. This will allow accurate measurements of the knee joint morphology so that diseases such as OA and patellar instability can be assessed.

MATERIALS AND METHODS:

- SKI10 MR images data set of 100 subjects, 60 for training and 40 for validation, was used. Skilled experts manually segmented the multi-class mask for the knee joint; the femur and tibia were labelled as 1 and 3, respectively.
- Automatic segmentation is done by a novel deep convolutional neural network (CNN), developed from U-Net (3), called Pseudo-3D U-Net. We chose deep learning over classical machine learning because training does not require any manual feature engineering. The network takes 3D images as input and outputs 2D images (Fig. 1).
- We compared the Pseudo-3D and a 2D U-Net volumetric performance in terms of the following metrics: Average Symmetric Surface Distance (ASSD), Root Mean Symmetric Surface Distance (RMSD), and Dice Similarity Coefficient (DSC) (Fig. 2, 3). A two-fold cross-validation technique was used to evaluate the performance of the model.

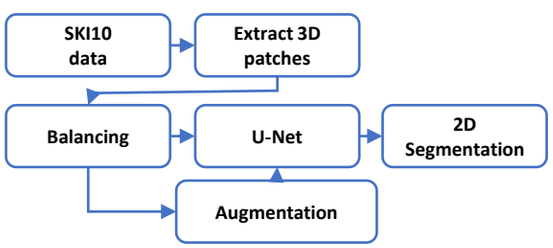

Fig. 1 – Algorithm dataflow

RESULTS:

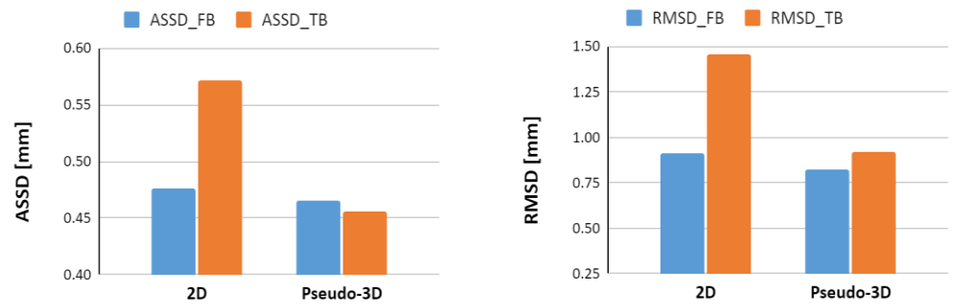

Fig. 2 – 2D U-Net and Pseudo-3D U-Net Evaluation of Segmentation Accuracy of Average Symmetric Surface Distance (ASSD) and Root Mean Square Symmetric Surface Distance (RMSD) for Femur (FB) and Tibia (TB) Bones on 40 subjects.

Table 1 - Comparison of Segmentation Accuracy (Average ± SD) of Our Methods and couple State-of-The-Art Methods.

	Femur Bone			Tibia Bone		
Reference	DSC	ASSD [mm]	RMSD [mm]	DSC	ASSD [mm]	RMSD [mm]
BCD [4]	97.3 ± 1.6	0.58 ± 0.45	1.73 ± 0.85	84.4 ± 4.1	0.47 ± 0.32	1.53 ± 1.05
SegNet [5]	—	0.56 ± 0.12	1.08 ± 0.21	—	0.50 ± 0.14	1.09 ± 0.28
2D U-Net	0.975 ± 0	0.475 ± 0.025	0.913 ± 0.115	0.974 ± 0.0005	0.571 ± 0.078	1.456 ± 0.444
Pseudo 3D U-Net	0.974 ± 0.0007	**0.465 ± 0.009**	**0.826 ± 0.035**	0.975 ± 0.0017	**0.455 ± 0.004**	**0.921 ± 0.022**

DSC, volumetric dice similarity coefficient, ASSD, average symmetric surface distance, RMSD, root mean square symmetric surface distance, SD, standard deviation

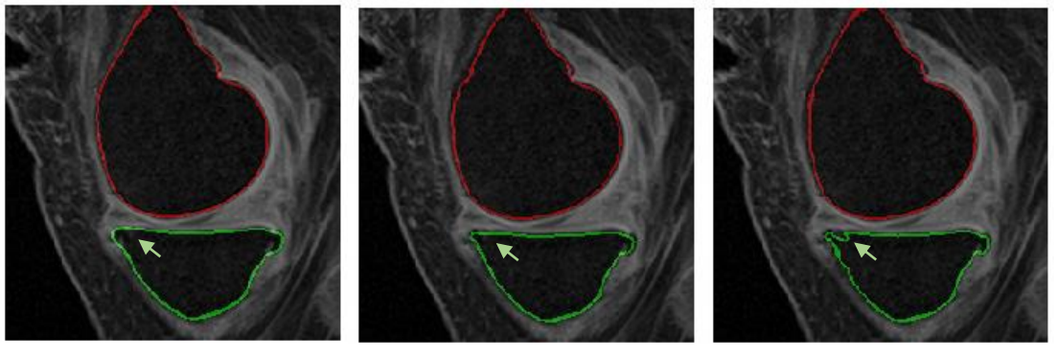

Fig. 3 – Segmentation of femur (red) and tibia (green) bones. Target (left), 2D U-Net (middle) which is less reliable than Pseudo-3D U-Net (right)

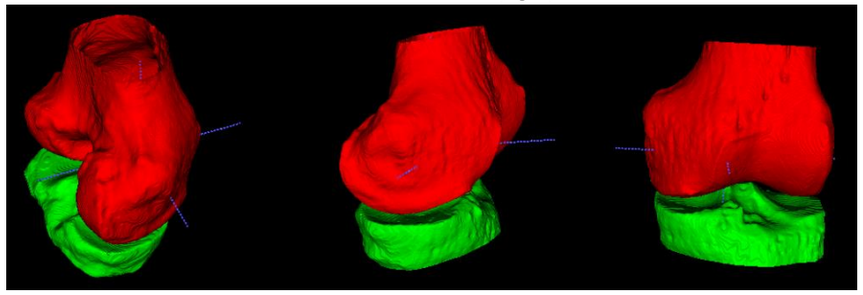

Fig. 4 – 3D rendering of the femur (red) and tibia (green) using the predicted values of the Pseudo-3D model

CONCLUSION:

- In this work, we showed the average of all the distances from points of the boundary of the predicted region to the boundary of ground truth, and vice versa performed better using Pseudo-3D than the 2D (Fig. 2) and presented State-of-the-Art (Table 1). As a result, we achieved an ASSD average of 0.465 ± 0.009 mm for FB and 0.455 ± 0.004 mm for TB, respectively. In addition, we improved the RMSD and ASSD for tibia bone by approx. 50 %, which enhanced the segmentation of the bones compared to the 2D network. We also obtained similar values of DSC for both bones, 0.974 for FB and 0.975 for TB, respectively. The Pseudo-3D captured global image information better and generated less ambiguity in terms of localization of ROIs (Fig. 3 - right).
- We rendered a 3D volume using the predicted values from Pseudo-3D U-Net (Fig. 4).

FUTURE WORK:

- This method will be used further to analyse the patellar instability, measure the morphology of the knee joint , and test it on a different set of data acquired in-house.

ACKNOWLEDGEMENTS

Thank you to my supervisors, lab colleagues, and Alexe Ciurea for resources, guidance, and encouragement.

CONTACT DETAILS

cristina.manoila@warwick.ac.uk

REFERENCES

(1) I. J. Wallace, S. Worthington, D. T. Felson, R. D. Jurmain, K. T. Wren, H. Maijanen,R. J. Woods, and D. E. Lieberman, "Knee osteoarthritis has doubled in prevalence since the mid-20th century, "Proceedings of the National Academy of Sciences, vol. 114, no. 35,pp. 9332–9336, 2017
(2) NHS, Osteoarthritis, https://www.nhs.uk/conditions/osteoarthritis/
(3) O. Ronneberger, P. Fischer, and T. Brox, "U-net: Convolutional networks for biomedical image segmentation," in International Conference on Medical image computing and computer-assisted intervention, Springer, 2015, pp. 234–241.
(4) H. Lee, H. Hong, and J. Kim, "Bcd-net: A novel method for cartilage segmentation of knee MRI via deep segmentation networks with bone-cartilage-complex modeling," in 2018 IEEE 15th International Symposium on Biomedical Imaging (ISBI 2018), IEEE, 2018,pp. 1538–1541
(5) F. Liu, Z. Zhou, H. Jang, A. Samsonov, G. Zhao, and R. Kijowski, "Deep convolutional neural network and 3D deformable approach for tissue segmentation in musculoskeletal Magnetic Resonance Imaging, "Magnetic resonance in medicine, vol. 79, no. 4, pp. 2379–2391, 2018