

MRI study of effectiveness of cervical spine immobilisation- a pilot study



Tim Crane, MB ChB MRCS (Ed)

Matthew Cooke, PhD MB ChB FRCS (Ed) FFAEM DipIMC

Richard Wellings, MB ChB FRCS (Ed) FRCR

Sarah Wayte, PhD

Joanne Higgins, BA (Hons) MA

Tim Crane

Specialist Registrar in Orthopaedics & Trauma, University Hospitals Coventry and Warwickshire, Coventry, UK

Matthew Cooke (author for reprint requests)

Reader in Emergency Care, Warwick Medical School, University of Warwick, Coventry, CV4 7AL, UK

Richard Wellings

Consultant Radiologist, University Hospitals Coventry and Warwickshire, Coventry, UK

Sarah Wayte

Clinical Scientist, University Hospitals Coventry and Warwickshire, Coventry, UK

Joanne Higgins

Research Fellow, University of Warwick, Coventry, UK

ACKNOWLEDGMENTS

The authors would like to acknowledge the help of all the volunteers and the MR staff who helped to undertake this study. We also thank Dr Sue Wilson for her statistical and methodological assistance and Professor Jeremy Dale for reviewing the manuscript.

Funding: University Hospitals Coventry and Warwickshire funded the MRI time.

Contributors: MWC, RW and SW initially designed the study, which was then modified in consultation with all the authors. SW designed the MR scanning protocol. TC undertook the recruitment and consent. MWC undertook the immobilisation application. RW assessed the MR scans. JH undertook the database management and initial analysis. TC wrote the original draft of the paper. All authors were involved in preparation of the final manuscript.

MWC is the guarantor of the paper.

ABSTRACT

Background Cervical spine fractures or dislocations may cause or exacerbate neurological injury if adequate immobilisation is not maintained. Although present guidelines dictate the use of a semi-rigid collar, head blocks and tape, the efficacy of these techniques remains unproven in normal or injured necks.

Methods Ten volunteers underwent sagittal cervical spine MR imaging using a combination of routine techniques and actively attempted full neck flexion and extension. Spinal movement was measured at each level from base of skull to T1.

Results Although any immobilisation technique provided a significant reduction in total net movement of the cervical spine, when compared with no immobilisation ($p < 0.001$), there was no difference in efficacy between techniques used. The currently recommended technique did not always provide the best immobilisation.

Conclusion The most effective technique to immobilise the cervical spine varied markedly between individuals and further research is required to determine the most effective and safest form of immobilisation.

[**Key words:** cervical-spine, immobilisation, movement, MR imaging, techniques]

INTRODUCTION

Those patients who sustain a traumatic unstable fracture or dislocation of the cervical spine are at risk of developing an associated neurological injury to the spinal cord. In order to prevent secondary neurological injury following fracture, or to limit the extent of neurological damage already incurred, international guidelines have evolved which dictate when spinal immobilisation should be utilised.

Current practice involves the application of a semi-rigid collar, head blocks and tape to the patient lying on a secure surface e.g. a spinal board or trolley, and this method is internationally accepted.¹ However when investigating their effectiveness and justifying their widespread use, it becomes apparent that the evidence supporting them thus far is not beyond question.

Several studies have employed a number of techniques to assess the efficacy of cervical spine immobilisation methods and compare them over recent years. Various types of semi-rigid collar have been tested in their ability to immobilise and restrict the movements of the cervical spine. By using plain radiographs, compass measurements and goniometric techniques, these collars, ranging from soft collars through semi-rigid and rigid collars to vacuum splint collars, have been graded in a number of studies as to the degree of stabilisation they provide.²⁻⁵

Further studies have involved the assessment of more elaborate immobilisation techniques with and without the use of collars, such as halo orthoses and sterno-

occipital mandibular immobiliser braces, with the use of photographic and radiological methods and a spine motion analyser.⁶⁻⁸ One previous study looked at active neck movement with a hand-held goniometer with only semi-rigid collar and sandbag / tape combinations.⁹ This found that sandbags and tape alone reduced gross movement more than the use of a semi-rigid collar alone, although the addition of a collar to sandbag / tape immobilisation further reduced neck extension.

Semi-rigid collars are not without complications. Principally, they can compromise the airway, especially in the multiply-injured trauma patient when mouth opening is limited and access to the anterior part of the neck is impaired when cricoid pressure or cricothyroidotomy may become necessary.¹⁰ Ventilating the immobilised patient poses challenges to the anaesthetist and techniques to intubate the patient whilst the semi-rigid collar remains in place have been attempted,¹¹⁻¹⁵ with varying degrees of success. It has been advocated that to perform orotracheal intubation safely, manual in-line immobilisation is the method of choice.¹⁶

As well as causing difficulty inserting CVP lines, semi-rigid collars may also cause pressure sores and lead to the development of haematomata or surgical emphysema beneath the collar. They are also thought to raise intracranial pressure by venous compression in the neck – a significant problem in the patient with a co-existing head injury.^{17,18}

Our study set out to investigate the extent of movement in the cervical spine in the unrestricted neck, and with standard immobilisation equipment and to quantify the effectiveness of these methods. MR imaging provided us with a quick, non-invasive

method of examining neck movement in the sagittal plane which does not visualise the method of restraint used (allowing the study to be conducted blind) and does not use ionising radiation. It allows visualisation of true cervical spine total movement rather than clinical techniques which measure movement of head in relation to the shoulders.

MATERIAL AND METHODS

Ten unpaid, healthy adult volunteers (3 male & 7 female) were recruited to participate in the study. Following approval for the protocol from the local ethics committee (Coventry Local Research Ethics Committee), criteria for exclusion from the study were accepted as: over 45 years of age, any current neck problems, any history of neck surgery or significant neck injury, any condition resulting in a restriction of neck movement or any contra-indication to MRI scanning.

Informed consent was obtained from all volunteers including explanation that appropriate follow-up would be arranged in the event of unexpected findings during the scan. The MRI scanner (1.0T Harmony system, Siemens) at University Hospitals Coventry & Warwickshire was used.

At the commencement of scanning, the flat base of the head block was secured to the scanner table. The same supervisor (an ATLS instructor) positioned each participant such that they were lying flat, with their occiput on the centre of the head block base. Instructions were repeated and attempted full active neck flexion and full extension

demonstrated, with care taken to ensure the occiput remained in contact with the head block base at all times.

In total, 8 scans of the cervical spine of each participant were taken – in a random sequence, the forms of immobilisation were used i.e. semi-rigid collar only, head blocks and tape only, both semi-rigid collar and head blocks and tape and no form of immobilisation. The same supervisor applied and removed the same items of standard equipment. For each form of immobilisation and without, the participant received instructions from the scanner operator via the intercom to adopt a flexed or extended position. Again, random orders of flexion and extension were used for each restraint.

The images obtained in the sagittal plane were all assessed by the same radiologist who was blinded as to the method of immobilisation employed. (MR images do not demonstrate the physical immobilisation device). The first method of analysis determined total movement by the difference in angle between only base of skull and the body of T1 – referred to as overall neck movement. (Photo 1)

Lines were drawn through the base of skull (taken as a line from the posterior foramen magnum to the tip of the hard palate) and through the centre of each vertebral body perpendicular to its long axis of adjacent vertebral bodies. For each scan, the angle of intersection between the relevant lines was measured, and hence movement between full flexion and full extension was assessed by the summated change in angles (irrespective of direction) between all the adjacent vertebral bodies. This second method of analysis will be referred to as summated movement.

It was therefore possible that the skull base and T1 could have had no relative movement (this is represented by the sum of each segment using negative values for

relative flexion and positive values for relative extension) and yet the spine in between moved at individual segments. This summation of movement at all levels, ignoring the direction of movement, reflects the true movement of the spine and therefore the risk of injury if any segment of the spine is unstable.

All data was entered on to a Microsoft Excel database and analysis of data was undertaken using SPSS.

RESULTS

Both overall and summated movement using all four techniques is summarised in Table 1.

T-test analysis revealed significant differences in the overall movement found between the “no immobilisation” group and all the other forms of immobilisation ($p < 0.001$), although there was no statistical difference found between any 2 of the restrained groups. This analysis was appropriate as a near normal distribution of data was confirmed, the ratio of skew to standard error being considerably less than ± 2 and therefore not significant.

Figure 1 shows overall movement. In 5 individuals, collar and blocks gave the best immobilisation, in 4 blocks only were most effective and in 1, collar only was most effective.

Figure 2 shows summated movement. In only 3 individuals did collar and blocks provide the best immobilisation, the remaining 7 individuals being immobilised best by blocks alone.

LIMITATIONS

This pilot study only examines ten healthy individuals and we are aware that our sample size is extremely small. The setting we used to assess cervical spine movement, i.e. the MR scanner in a radiology department was also very artificial and controlled and different to the environment where immobilisation for traumatic injury is instituted and initially managed. Equally our participants were all cooperative with neither an acute neck nor associated head injury. Our study chose only to investigate movement in the sagittal plane, rather than all three dimensions.

DISCUSSION

Our results show that the participants' cervical spine movements both with and without immobilisation varied considerably between individuals. By assessing movement of the head on the shoulders (overall movement), ignoring all movement within the neck, our results demonstrated that the performance of each immobilisation device differed from that when considering the summated movement (irrespective of direction) at each level from base of skull to T1. In other words, collar and blocks prevented the most movement in 5/10 individuals when looking at movement of base of skull relative to T1, but blocks only prevented the most movement in 7/10 individuals across the cervical vertebral bodies, i.e. "snaking" type movement.

This pattern of paradoxical motion has been noted with goniometric techniques previously ¹⁹, leading to the suggestion that one should match the level-specific efficacy of the immobilisation device used to the level of injury. Relatively little is known about the anatomical dynamics of cervical spine movement in either the healthy or injured subject. In the normal neck, lordosis is lost by moving from extension to flexion ²⁰, and the ratio of spinal canal to spinal cord cross-sectional area is increased with minimal flexion.²¹

This study of healthy volunteers implies that any form of immobilisation was better than none, but between individuals the best form of immobilisation was variable. Intervertebral motion has been found to be greater at injury levels ²², however, knowledge of the nature of movement in the injured neck remains poor. It would be unethical to test this therefore we must extrapolate the best immobilisation of the cervical spine from studies in healthy subjects.

Our pilot study raises the issue of the effectiveness of our current “gold standard” technique and paves the way for further research to investigate its use. If further studies fail to justify the routine use of the semi-rigid collar, given its risk of complications, it’s role in spinal immobilisation may need to be modified.

Acknowledgments

The authors would like to acknowledge the help of all the volunteers and the MR staff who helped to undertake this study.

We also thank Dr Sue Wilson for her statistical and methodological assistance and Professor Jeremy Dale for reviewing the manuscript.

Funding: University Hospitals Coventry and Warwickshire funded the MRI time.

Contributors: MWC, RW and SW initially designed the study, which was then modified in consultation with all the authors. SW designed the MR scanning protocol. TC undertook the recruitment and consent. MWC undertook the immobilisation application. RW assessed the MR scans. JH undertook the database management and initial analysis. TC wrote the original draft of the paper. All authors were involved in preparation of the final manuscript.

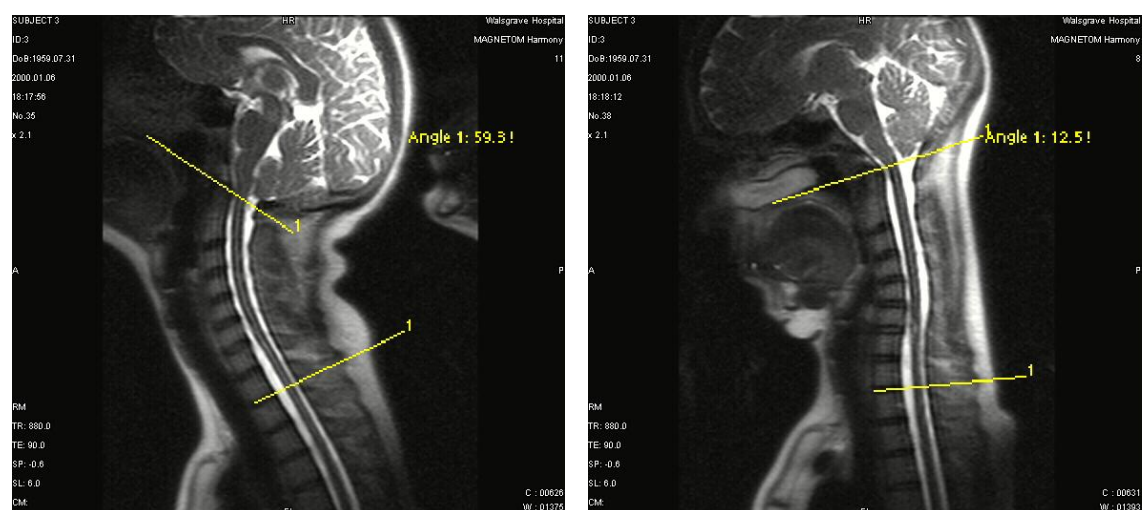


Photo 1. Marks for calculation of movement in flexion and extension of the neck

	Overall neck movement (95% CI)	Summated movement (95% CI)
No immobilisation	72°(55°-89°)	90°(77°-103°)
Collar only	41°(29°-53°)	58°(49°-67°)
Blocks only	35°(20°-50°)	52°(41°-63°)
Collar & blocks	29°(17°-41°)	53°(49°-57°)

Table 1. Mean Movement of cervical spine with each form of immobilisation

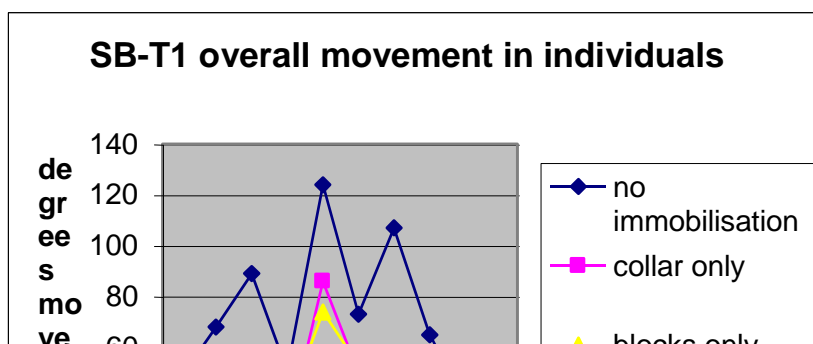


Figure 1. Overall movement of neck in each individual

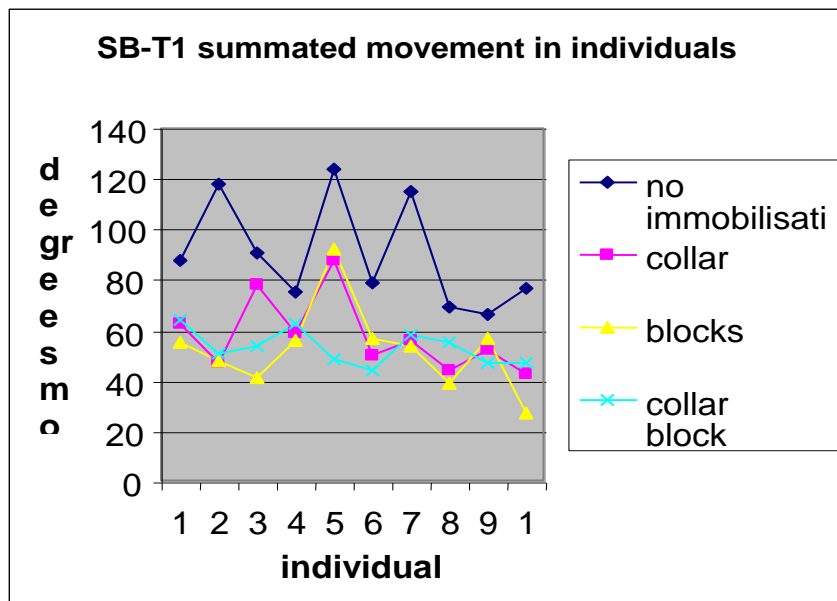


Figure 2. Summated movement of neck in each individual

REFERENCES

1. American College of Surgeons Committee on Trauma. Chapter 1 Initial Assessment and Management. In: Advanced Trauma Life Support for Doctors Student Course Manual. 1997. 27.
2. Alberts LR, Mahoney CR, Neff JR. Comparison of the Nebraska collar, a new prototype cervical immobilization collar, with three standard models. *J Orth Trauma* 1998;12(6):425-30.
3. McCabe JB, Nolan DJ. Comparison of the effectiveness of different cervical immobilization collars. *Ann Emerg Med* 1986;15(1):50-3.
4. Askins V, Eismont FJ. Efficacy of five cervical orthoses in restricting cervical motion. A comparison study. *Spine* 1997;22(11):1193-8.
5. Rosen RB, McSwain NE, Arata M, Stahl S, Mercer D. Comparison of 2 new immobilization collars. *Ann Emerg Med* 1992;21(10):1189-95.
6. Cline JR, Scheidel E, Bigsby EF. A comparison of methods of cervical immobilization used in patient extrication and transport. *J Trauma* 1985;25(7):649-53.
7. Chandler DR, Nemejc C, Adkins RH, Waters RL. Emergency cervical-spine immobilization. *Ann Emerg Med* 1992;21(10):1185-8.

8. Sandler AJ, Dvorak J, Humke T, Grob D, Daniels W. The effectiveness of various cervical orthoses. An in vivo comparison of the mechanical stability provided by several widely used models. *Spine* 1996;21(14):1624-9.
9. Podolsky S, Baraff LJ, Simon RR, Hoffman JR, Larmon B, Ablon W. Efficacy of cervical spine immobilization methods. *J Trauma* 1983;23(6):461-5.
10. Elliot JM. Intubation and suspected cervical spine injury. *Anaesthesia* 1996;51(9):891.
11. Wakeling HG, Nightingale J. The intubating laryngeal mask airway does not facilitate tracheal intubation in the presence of a neck collar in simulated trauma. *Br J Anaesthesia* 2000;84(2):254-6.
12. Gabbott DA. Laryngoscopy using the McCoy laryngoscope after application of a semi-rigid collar. *Anaesthesia* 1996;51(9):812-4.
13. Morley A, Haji-Michael PG, Mahoney P. Cervical spine control during prehospital tracheal intubation of trauma victims. *Anaesthesia* 1995;50(7):661-2.
14. Pennant JH, Pace NA, Gajraj NM. Role of the laryngeal mask airway in the immobile cervical spine. *J Clin Anaesthesia* 1993;5(3):226-30.

15. Wakeling HG, Nightingale J. The intubating laryngeal mask airway does not facilitate tracheal intubation in the presence of a neck collar in simulated trauma. *Br J Anaes* 84(2):254-6, 2000 Feb
16. Heath KJ. The effect of laryngoscopy of different cervical spine immobilisation techniques. *Anaesthesia* 1994;49(10):843-5.
17. Raphael JH, Chotai R. Effects of the semi-rigid collar on cerebrospinal fluid pressure. *Anaesthesia* 1994;49(5):437-9.
18. Hunt K, Hallworth S, Smith M. The effects of rigid collar placement on intracranial and cerebral perfusion pressures. *Anaesthesia* 56(6):511-3, 2001 Jun
19. Hughes SJ. How effective is the Newport / Aspen collar? A prospective radiographic evaluation in healthy adult volunteers. *J Trauma* 1998;45(2):374-8.
20. Lin RM, Tsai KH, Chu LP, Chang PQ. Characteristics of sagittal vertebral alignment in flexion determined by dynamic radiographs of the cervical spine. *Spine* 2001;26(3):256-61.
21. De Lorenzo RA, Olsen JE, Boska M, et al. Optimal positioning for cervical immobilization. *Ann Emerg Med* 1996;28(3):301-8.

22. Anderson PA, Budorick TE, Easton KB, Henley MB, Saliccioli GG. Failure of halo vest to prevent in vivo motion in patients with injured cervical spines. *Spine* 1991;16(10 Suppl):S501-5.